

RESEARCH ARTICLE

Open Access



C-Nail versus plate osteosynthesis in displaced intra-articular calcaneal fractures—a comparative retrospective study

Eva Steinhausen^{1,2*}, Wolfgang Martin^{1†}, Rolf Lefering³, Sven Lundin¹, Martin Glombitza¹, Bastian Mester², Nikolaus Brinkmann¹ and Marcel Dudda^{1,2}

Abstract

Background: Locking plate osteosynthesis via an L-shaped lateral approach is the gold standard in treating displaced intra-articular calcaneal fractures. High complication rates are known for this approach. The most frequent complications are wound edge necrosis and superficial wound infections. To reduce complication rates, a locking intramedullary nail (C-Nail) was developed that can be implanted minimally invasively via a sinus tarsi approach. We compared the postoperative complication rate and the outcome of plate osteosynthesis versus C-Nail in displaced intra-articular calcaneal fractures.

Methods: All patients with calcaneal fractures who received osteosynthesis with either plate or C-Nail between January 2016 and October 2019 in our institution were retrospectively analyzed. A subgroup analysis was performed with matched pairs (matching Sanders type, age, Böhler's angle postoperative in normal range, 33 pairs). Endpoints were postoperative complication rate, bone healing, full weight-bearing and functional outcome. Treatment groups were compared using Fisher's exact test for binary data, and Mann-Whitney *U*-test for continuous data. A *p*-value < 0.05 was considered statistically significant.

Results: One hundred and one calcaneal fractures were included (C-Nail *n* = 52, plate *n* = 49). Patients with C-Nail developed significantly less postoperative complications (*p* = 0.008), especially wound edge necrosis (*p* < 0.001). Screw malposition was found more often in the C-Nail group. The rates of achieving full weight-bearing as well as bone healing were comparable in both groups, but in each case significant faster in the C-nail subgroup. The results of the matched-pairs analysis were comparable.

(Continued on next page)

* Correspondence: Eva.Steinhausen@uni-due.de

†Eva Steinhausen and Wolfgang Martin contributed equally to this work.

¹Department of Orthopedic and Trauma Surgery, BG Klinikum Duisburg, University of Duisburg-Essen, Großenbaumer Allee 250, 47249 Duisburg, Germany

²Department of Trauma, Hand and Reconstructive Surgery, University Hospital Essen, University of Duisburg-Essen, Essen, Germany

Full list of author information is available at the end of the article



© The Author(s). 2021 **Open Access** This article is licensed under a Creative Commons Attribution 4.0 International License, which permits use, sharing, adaptation, distribution and reproduction in any medium or format, as long as you give appropriate credit to the original author(s) and the source, provide a link to the Creative Commons licence, and indicate if changes were made. The images or other third party material in this article are included in the article's Creative Commons licence, unless indicated otherwise in a credit line to the material. If material is not included in the article's Creative Commons licence and your intended use is not permitted by statutory regulation or exceeds the permitted use, you will need to obtain permission directly from the copyright holder. To view a copy of this licence, visit <http://creativecommons.org/licenses/by/4.0/>. The Creative Commons Public Domain Dedication waiver (<http://creativecommons.org/publicdomain/zero/1.0/>) applies to the data made available in this article, unless otherwise stated in a credit line to the data.

(Continued from previous page)

Conclusions: The postoperative complication rate was significantly lower in the C-Nail group. The C-Nail appears to be a successful alternative in the treatment of calcaneal fractures, even in Sanders IV fractures because of the minimal-invasive implantation as well as the high primary stability. Long-term analysis of this new implant including elaboration on functional outcome is planned.

Trial registration: Deutsches Register Klinischer Studien (DRKS) [DRKS00020395](https://www.drks.de/DRKS00020395). Date of registration 3 January 2020.

Keywords: Calcaneal fracture, Sinus tarsi approach, Extensile lateral approach, Calcaneal nail

Background

The surgical treatment of displaced intra-articular calcaneal fractures remains challenging. It aims at the most anatomic reduction possible while restoring joint congruence as well as height, length, and width of the calcaneus [1–3]. Thereby typical long-term consequences such as pain and weight-bearing insufficiency due to post-traumatic subtalar arthrosis up to subtalar arthrodesis shall be prevented or at least diminished [4].

Depending on the conditions of the soft tissue and the type of fracture, various therapeutic procedures are available for calcaneal fractures: conservative treatment [5, 6], open reduction and (locking) plate osteosynthesis [7–9], percutaneous respectively minimal-invasive reduction and plate, screw or K-wire osteosynthesis [3, 7, 9–11], arthroscopically assisted reduction [8, 12], and treatment with external fixator [13] up to primary subtalar arthrodesis, in particular in case of multi-fragmentary calcaneal fractures [14].

The gold standard for displaced intra-articular calcaneal fractures is open reduction and plate osteosynthesis via an L-shaped lateral approach [7, 9, 13, 15–17]. However, high complication rates of up to 47.4% are known for this approach [4, 7, 9, 16–20]. The most frequent complications are wound edge necrosis and superficial wound infections, but deep wound infections/osteomyelitis are also regularly reported.

A sinus tarsi approach causes less complications than an L-shaped lateral approach—particularly with regard to wound edge necrosis and superficial wound infections [4, 11, 19, 21, 22]. The reduction of the posterior facet seems to be comparably good [19, 22, 23].

The C-Nail® was developed to reduce the high complication rate after lateral approach. It is a locking nail that can be implanted minimally invasively [24–26]. The reduction of the subtalar articular surface is performed via the above-mentioned sinus tarsi approach. The initial results are promising. To date, however, there have been only a few clinical studies on this new implant [1, 16, 24]. Randomized studies as well as long-term results are lacking.

This retrospective study compares the (early) postoperative complication rate as well as the outcome of C-Nail® versus plate osteosynthesis in displaced intra-articular calcaneal fractures.

We hypothesized that using the C-nail in patients with displaced intra-articular calcaneal fractures results in less early-postoperative complications with comparable long-term results when compared to plate osteosynthesis.

Methods

C-Nail

The C-Nail® (manufacturer: Medin, Neustadt in Moravia, Czech Republic; distribution in Germany by tantum AG, Neumünster) is a locking nail made of implant steel. It has a length of 65 mm and a diameter of 8 mm. The nail can be extended with endcaps from 5 to 20 mm to a maximum of 85 mm.

The main tuberosity fragment can be reduced toward the sustentacular fragment percutaneously by a Schanz screw. By applying traction and valgus or varus stress to the Schanz screw, shortening, and varus/valgus malposition of the tuberosity fragment can be corrected. Temporary fixation of the position of the tuberosity fragment is performed with Kirschner wires. A sinus tarsi approach is used for open reduction and control of articular reduction. After reduction, the posterior facet is stabilized with two screws. The joint block and the anterior process are repositioned to the tuberosity and are temporarily fixed with Kirschner wires. Not till then a vertical incision below the attachment of the Achilles tendon is made and a guide-wire is placed toward the center of the calcaneocuboid joint. After that, the C-nail is placed. Kirschner wires and screws can be implanted with an aiming device. Up to seven screws can be inserted to stabilize even multi-fragmentary fractures. Finally, the aiming device is removed and an end cap is applied.

The skills of this implant are the minimal-invasive reduction and implantation as well as the reduction via the less complicative sinus tarsi approach. The pitfalls are a limited view to the articular surface due to the sinus tarsi approach, the required reduction before introducing the nail and last but not least a learning curve.

According to the manufacturer, indications are displaced intra-articular fractures (type Sanders I-IV) and unstable extra-articular two-part fractures [16]. Contraindications are unsealed apophyseal joints, infected soft tissue, and calcanei with a length of < 65mm [16, 26].

Since the introduction of the C-nail® in our institution in July 2016, open reduction and plate osteosynthesis are performed less and less frequently. The decision as to which osteosynthesis method is used is determined individually by surgeons' preference. In order to obtain comparably large groups, patients with displaced intra-articular calcaneal fractures are evaluated from January 2016 onwards.

Patient cohort

A retrospective analysis was conducted and included patients with displaced intra-articular calcaneal fractures, who were treated in our institution between January 2016 and October 2019 either with C-Nail® or with plate osteosynthesis. Inclusion criteria were at least one consultation postoperative, as a general rule 6 weeks postoperatively. Due to the retrospective design of this study, we had no standardized postoperative follow-up protocol. Patients younger than 18 years, treated with another procedure or a conservative approach, and those who did not appear for follow-up at our clinic postoperatively were excluded.

In addition to our main analysis, we performed a subgroup analysis with matched pairs. Matching was done regarding Sanders type, age, and Böhler's angle postoperative in normal range.

Fracture type and epidemiological data as well as peri- and postoperative clinical courses were evaluated. Follow-up ended by March 2020.

The primary endpoint is the early-postoperative complication rate. Secondary endpoints are reconstruction of the calcaneus, bone healing, achievement of full weight-bearing, and functional outcome. In addition, post-traumatic subtalar arthroses, subtalar arthrodesis, and all complications including late infections, screw malposition, non-unions, and reoperations were evaluated.

Epidemiologic data and the pre-, peri-, and postoperative clinical course were compiled from the digital patient files and processed pseudonymously. Bone healing and assessment of intra-articular surface were quantified by evaluating x-ray or CT scan. Screw malposition was defined as screw positioning in the subtalar joint as well as overlapping the corticalis > 2 mm.

The functional outcome was assessed the earliest 6 months postoperative with the American Orthopaedic Foot and Ankle Society (AOFAS) Ankle-Hindfoot Scale. Ninety-five to 100 points were defined as excellent results, 75–94 points as good results, and 51–74 points as fair results.

Ninety-two patients with 101 calcaneal fractures (C-Nail $n = 53$, plate $n = 49$) were retrospectively evaluated. Thereof, 76 patients with 82 calcaneal fractures had a follow-up > 6 months (C-Nail $n = 45$, plate $n = 37$) and thus the AOFAS score was analyzed in this group.

Surgical procedure

Surgery was performed by surgeons of the Department of Foot Surgery. This ensures that the surgeons have sufficient expertise with both strategies. Surgeon's preference was decisive, if both procedures were possible.

The follow-up consisted of evaluating the endpoints in line with the follow-up care in our consultation hours. All patients were postoperatively treated according to our in-house concept. For 6 weeks postoperatively, patients should avoid weight-bearing of their foot, respectively wear an orthosis with partial weight-bearing. After 6 weeks, patients can perform full weight-bearing.

Statistics

Treatment groups were compared using Fisher's exact test for binary data, and Mann-Whitney U -test for continuous data. For descriptive analysis, the median was given in addition to mean and standard deviation (SD) in case of a skewed distribution. A p -value < 0.05 was considered statistically significant. Statistical analysis was performed using SPSS (Version 24, IBM Inc., Armonk, NY, USA).

Results

Ninety-two patients with 101 calcaneal fractures (C-Nail $n = 52$, plate $n = 49$) were retrospectively evaluated (Fig. 1). Thirty-three matched pairs underwent subgroup analysis.

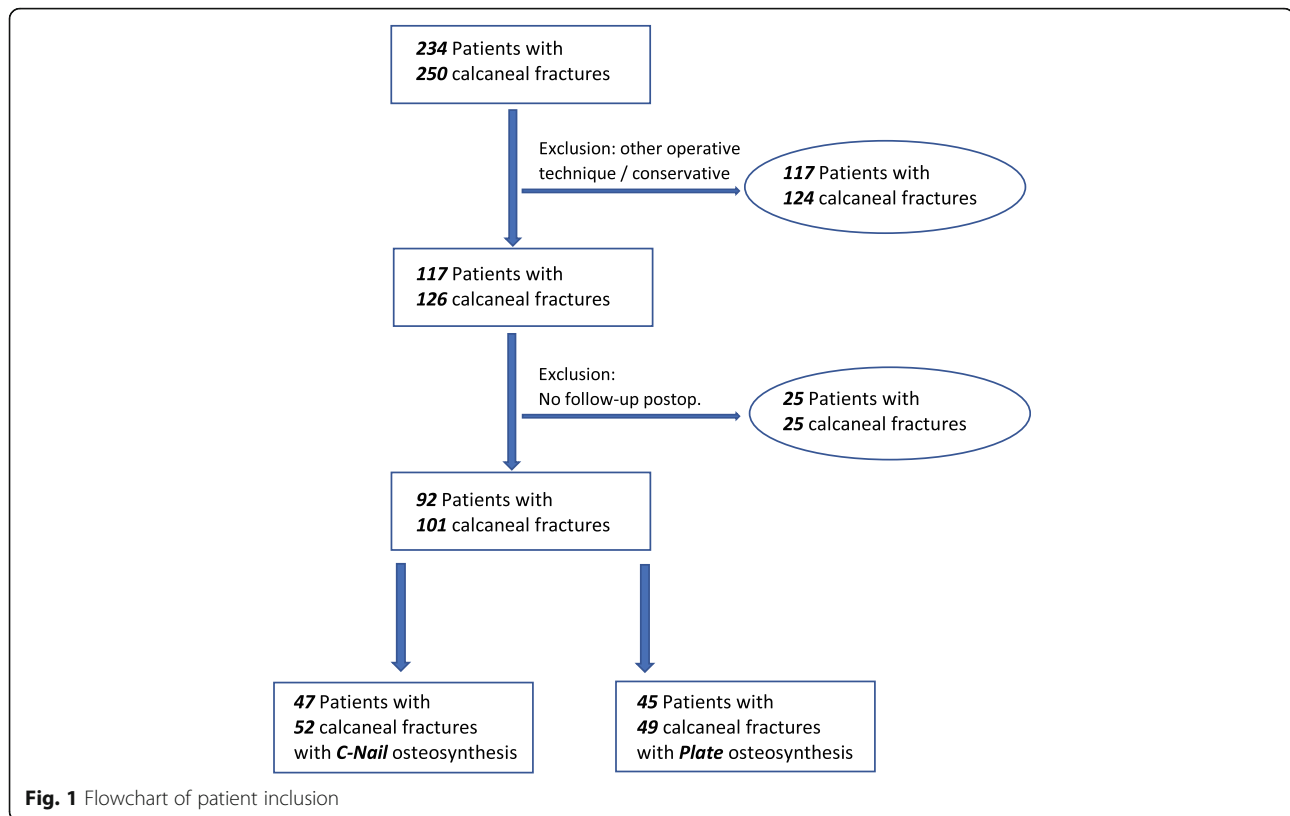
Epidemiology/preoperative parameters

The two main groups were comparable in terms of sex, type of injury, and type of fracture. However, patients in the C-Nail group were significantly older; patients in the plate group, on the other hand, had a significantly more frequent Sanders IV fracture and a significantly smaller Böhler's angle preoperatively (Table 1). These differences between groups do not appear in the subgroup with matched pairs.

The following results refer to the main groups. The results of the matched-pairs subgroup analysis are described at the end of the chapter.

Perioperative parameters

The average duration of surgery was significantly shorter when using C-Nail. Postoperatively, the Böhler's angle was within the normal range in 85 patients, more frequently in the C-Nail group, but not significantly. Overall, the average Böhler's angle was significantly smaller postoperatively in the plate group, whereas the average surgical correction of the Böhler's angle was comparable between both groups (Table 2). No loss of reduction was found in any group during follow-up.



Follow-up

A total of 89 patients reached full weight-bearing during follow-up, significantly faster in the C-Nail group (C-Nail 12.9 ± 8.5 weeks, plate 15.4 ± 5.0 weeks, $p < 0.001$). In 85 patients, fracture healing was found by the end of follow-up, also significantly faster in the C-Nail group (Table 2).

Comparable results were found in functional outcome. The sum of the AOFAS ankle-hindfoot score in patients who had a follow-up of at least 6 months was on average 79.4 points without significant differences between the two groups. In the individual items of the AOFAS score, no significant differences between both groups were

found either. Thus, the overall functional outcome was good.

Complications

A total of 38 patients (37.6%) developed complications during follow-up, significantly more frequently in the plate group. In 22 patients, these complications resulted in at least one additional surgery, with approximately the same frequency in both groups.

Wound edge necrosis was significantly more frequent in the plate group, but not all of them were subject to revision. Deep infections with consecutive osteomyelitis of the calcaneus did not differ significantly in frequency

Table 1 Comparison of epidemiologic and preoperative data between C-Nail and plate osteosynthesis

	Total	C-Nail	Plate	Significance (p)
		n = 47 patients	n = 45 patients	
Gender (m)	87 (86%)	44 (84%)	43 (87%)	0.78
Age (years)	46.6 ± 12.1	49.2 ± 13.1	43.9 ± 10.4	0.019
		n = 52 fractures	n = 49 fractures	
Trauma (unilateral, bilateral, multiple trauma in stable condition)	59/22/20 (58%/22%/20%)	29/13/10 (56%/25%/19%)	30/9/10 (61%/18%/21%)	0.72
Type of fracture (open)	6 (6%)	2 (4%)	4 (8%)	0.43
Classification (Sanders type IV)	72 (71%)	32 (62%)	40 (82%)	0.026
Böhler's angle preoperative (median)	16.0 ± 10.0 (15.0)	17.7 ± 9.3 (17.5)	14.2 ± 10.4 (13.0)	0.028

Table 2 Comparison of peri- and postoperative data between C-Nail and plate osteosynthesis

	Total, n = 101	C-Nail, n = 52	Plate, n = 49	Significance (p)
Perioperative data				
Time between accident and operation (days)	11.6 ± 5.5	11.7 ± 6.4	11.6 ± 4.5	0.63
Hospital stay (days), median	15.7 ± 18.2, 9	13.2 ± 12.4, 9	18.3 ± 22.6, 10	0.49
Duration of operation (min), median	108.1 ± 32.1, 101	98.2 ± 27.8, 93	118.6 ± 33.2, 112	0.001
CT postoperative performed (n)	72 (71%)	38 (73%)	34 (69%)	0.83
Böhler's angle postoperative, median	26.9 ± 6.5, 28	28.3 ± 6.0, 28	25.5 ± 6.7, 26	0.039
Böhler's angle postoperative in normal range (n)	85 (84%)	47 (90%)	38 (78%)	0.10
Böhler's angle difference post-preop., median	10.9 ± 8.8, 11.0	10.6 ± 8.3, 9.5	11.3 ± 9.4, 11.0	0.30
Postoperative data				
Time duration of follow-up (months)	14.2 ± 12.3	14.0 ± 8.9	14.5 ± 15.2	0.22
Full weight-bearing achieved (n)	89 (88%)	49 (94%)	40 (82%)	0.07
Time duration to full weight-bearing (weeks), median	14.0 ± 7.2, 12	12.9 ± 8.5, 10	15.4 ± 5.0, 14	< 0.001
Bone healing achieved	85 (84%)	45 (87%)	40 (82%)	0.59
Time duration to bone healing (weeks), median	15.6 ± 11.3, 13	14.3 ± 13.2, 11	17.1 ± 8.7, 14	0.002
Shoe inlay, orthopedic shoe	20 (22%)/42 (47%)	11 (22%)/21 (43%)	9 (22%)/21 (51%)	0.68
Planned implant removal	33 (38%)	17 (35%)	16 (42%)	0.66
Subtalar arthrosis	30 (37%)	12 (27%)	18 (49%)	0.07
Subtalar arthrodesis	6 (7%)	2 (4%)	4 (11%)	0.40

between the two groups. Premature implant removal or free tissue transfer due to infection or soft tissue defect were necessary in both groups without significant differences. A screw malposition was found more frequently in the C-Nail group. Non-unions were found equally frequently in both groups (Table 3).

Matched pairs (n = 33 pairs)

Böhler's angle preoperative as well as Böhler's angle postoperative was comparable in both groups. The duration of operation was significant shorter in the C-Nail group. The rates of achieving full weight-bearing and bone healing were comparable, but in each case significantly faster in the C-nail subgroup. Patients of the plate subgroup developed significantly more often subtalar

arthroses. Complications in general were more often seen in the plate subgroup with significant more wound edge necroses in the plate subgroup, too. Other complications occurred in both subgroups without significant differences (Table 4).

All in all, the results of the subgroup analysis are comparable to those of the main group analysis.

Discussion

The optimal treatment of displaced intra-articular calcaneal fractures is challenging and still controversial [7, 9, 10, 19, 24, 27, 28]. The development of postoperative wound complications is a major concern in the treatment of calcaneal fractures with extensile approaches [3].

Table 3 Comparison of postoperative complications between C-Nail and plate osteosynthesis

	Total, n = 101	C-Nail, n = 52	Plate, n = 49	Significance (p)
Total number of complications	38 (38%)	13 (25%)	25 (51%)	0.008
Further operations	22 (22%)	12 (23%)	10 (20%)	0.81
Wound edge necrosis	21 (21%)	3 (6%)	18 (37%)	< 0.001
Superficial wound infection	16 (16%)	5 (10%)	11 (22%)	0.10
Osteomyelitis	9 (9%)	4 (8%)	5 (10%)	0.74
Infection with one/multiple pathogens	5 (5%)/6 (6%)	2 (4%)/2 (4%)	3 (6%)/4 (8%)	0.28
Malposition of screws	7 (7%)	6 (12%)	1 (2%)	0.11
Local or free tissue transfer	7 (7%)	3 (6%)	4 (8%)	0.71
Early implant removal	11 (11%)	5 (10%)	6 (12%)	0.76
Non-union	7 (8%)	4 (9%)	3 (7%)	1.00

Table 4 Subgroup analysis with matched pairs (matching Sanders type, age, and Böhler's angle postoperative in normal range); comparison of postoperative data and complications between C-Nail and plate osteosynthesis

	Total, n = 66 (matched pairs n = 33)	C-Nail, n = 33 patients	Plate, n = 33 patients	Significance (p)
Age (years)	44.3 ± 9.7	44.8 ± 10.3	43.8 ± 9.3	
Sanders IV	48 (73%)	24 (73%)	24 (73%)	
Böhler's angle in normal range	62 (94%)	31 (94%)	31 (94%)	
Preoperative data				
Type of fracture (open)	3 (5%)	1 (3%)	2 (6%)	0.56
Böhler's angle preoperative	16.2 ± 10.5	16.9 ± 9.9	15.6 ± 11.2	0.39
Perioperative data				
Duration of operation (min)	106.6 ± 28.8	97.2 ± 22.5	116.0 ± 31.4	0.015
Böhler's angle postoperative	27.9 ± 5.4	28.7 ± 5.8	27.1 ± 5.1	0.27
Böhler's angle difference post-preop.	11.6 ± 9.9	11.8 ± 9.1	11.5 ± 10.8	0.60
Postoperative data				
Time duration of follow-up (months)	15.9 ± 13.5	14.3 ± 9.4	17.5 ± 16.6	0.99
Bone healing achieved	60 (91%)	30 (91%)	30 (91%)	1.00
Time duration to bone healing (weeks)	14.0 ± 8.0	10.6 ± 4.4	17.4 ± 9.3	< 0.001
Full weight-bearing achieved (n)	61 (92%)	31 (94%)	30 (91%)	0.64
Time duration to full weight-bearing (weeks)	12.9 ± 5.4	10.7 ± 4.8	15.2 ± 5.2	< 0.001
Subtalar arthrosis	17 (30%)	5 (17%)	12 (43%)	0.04
Subtalar arthrodesis	4 (7%)	2 (7%)	2 (7%)	1.00
AOFAS	81 ± 15.4	80 ± 17	81 ± 13.8	0.91
Complications				
Total number of complications	21 (32%)	7 (21%)	14 (42%)	0.06
Further operations	12 (18%)	6 (18%)	6 (18%)	1.00
Malposition of screws	4 (6%)	3 (9%)	1 (3%)	0.34
Wound edge necrosis	13 (20%)	2 (6%)	11 (33%)	0.005
Superficial wound infection	8 (12%)	2 (6%)	6 (18%)	0.13
Osteomyelitis	4 (6%)	1 (3%)	3 (9%)	0.30
Infection with one/multiple pathogens	1 (2%)/4 (6%)	0 (0%)/1 (3%)	1 (3%)/3 (9%)	0.34
Non-union	2 (3%)	0 (0%)	2 (7%)	0.16

The aim of our study is to compare the (early) postoperative complication rate as well as the outcome of C-Nail® versus plate osteosynthesis in displaced intra-articular calcaneal fractures.

The C-Nail group developed significantly fewer postoperative complications and in particular wound edge necroses, whereas the number of deep infections/osteomyelitis and follow-up operations were comparable. The C-Nail group reached full weight-bearing and bone healing faster (Fig. 2). Comparable results were found in our subgroup analysis with matched pairs.

To date, there have been only few clinical studies on the use of the C-Nail® [1, 16, 24]. So far, only one study by Zeman et al. [1] compared the use of C-Nail® with the gold standard plate osteosynthesis via a lateral

approach. Neither the rate of wound edge necrosis nor that of deep infections differs significantly between the groups in this study. The functional outcome for plate and C-Nail® are also comparably good. However, in this study the two groups are of different sizes (plate $n = 217$; C-nail $n = 19$). Furthermore, only Sanders II and III fractures, but no Sanders IV fractures, were treated with C-Nail in this study, so that the comparability to our study is limited. The authors conclude that the C-Nail® can be successfully used as the method of first choice in Sanders type II and III fractures.

Zwipp et al. [24] report on 106 calcaneal fractures that were treated with C-Nail®. A control group is missing. The rate of superficial wound edge necroses and deep infections is low at 1.9% and 0.9%, respectively. Zwipp

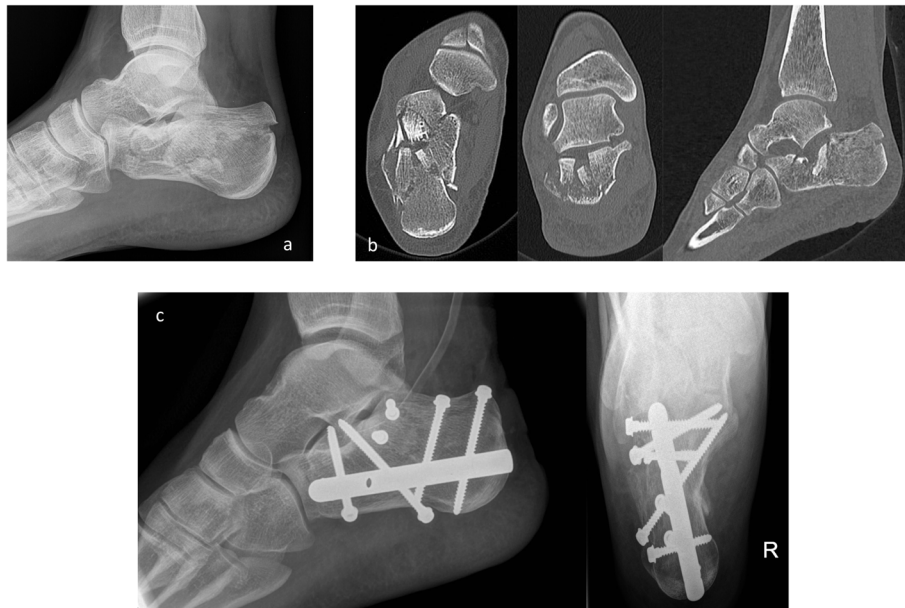


Fig. 2 Calcaneal fracture, osteosynthesis with C-nail. **a** Preoperative x-ray. **b** Preoperative CT scan. **c** Osteosynthesis with C-nail, postoperative x-ray

et al. [24] conclude that the minimally invasive implantation of the C-Nail® with reduction via a sinus tarsi approach leads to low rates of postoperative complications.

Pompach et al. [16] report in their study on the surgical technique of the C-Nail®. They analyzed the same patients as reported in the study of Zwipp et al. [24].

The authors of the latter two clinical studies [16, 24] are patent owners of the C-Nail®, so that a conflict of interest cannot be completely ruled out.

There are numerous studies on the complication rates after osteosynthesis of a calcaneal fracture over an extended lateral approach and further studies comparing these with the complication rates after sinus tarsi approach or other minimally invasive approaches in the current literature [4, 11, 19, 21–23]. In a meta-analysis by Mehta et al. [4], there were significantly fewer postoperative complications after sinus tarsi than after extended lateral access. In general, postoperative wound infection rates after the sinus tarsi approach range between 0 and 9.1% [11, 19, 29–31].

In our study, the early-postoperative complication rate was significantly lower in the C-Nail group than in the plate group with comparably good reduction results. However, not all wound edge necroses or superficial wound infections were subject to revision, many of them could be successfully treated by conservative wound management. It is also notable that the early-postoperative complication rate in the C-Nail group shown in our study—although lower than in the plate group—is nevertheless higher than described in other C-Nail-studies [1, 16, 24]. One explanation may be the higher number of complex fractures, including Sanders IV fractures with often primarily critical soft tissues.

De Groot et al. [28] conclude that short-term postoperative complications do not influence mid- to long-term outcome. The findings of our study do not lead to the same result. Even in conservatively successfully treated wound margin necroses, the duration of rehabilitation was extended with delayed weight-bearing of the affected limb. Thus, no significant difference was found between our groups with regard to the achievement of full weight-bearing and radiological consolidation. However, the C-Nail group—with significantly fewer complications—achieved both full weight-bearing and bone healing significantly faster. Based on our analysis, we assume that postoperative complications negatively influence at least the mid-term outcome.

The duration of surgery is indicated by some authors as a risk factor for postoperative wound healing disorders [4, 9, 32]. In their meta-analysis, Mehta et al. [4] describe a shorter duration of surgery when using the sinus tarsi approach compared to the extended lateral approach. For our patient cohort, both of these factors apply: The patients treated with C-Nail® had a significantly shorter duration of surgery and fewer postoperative wound healing disorders.

According to Court-Brown et al. [33], the deep infection rate correlates with surgical experience. Swords et al. also describe that complications decrease and results improve with surgeons' experience [34]. A sufficient level of expertise is guaranteed for both groups in our institution since the calcaneal fractures are treated by surgeons who are experienced in foot surgery.

Our analysis noticed an increased rate of screw malposition in the C-Nail group. This complication was found

particularly in the initial phase and, in our opinion, it should be seen as sign of a learning curve for a new implant. Amlang et al. [26] also refer to a learning curve in the surgical technique for the use of C-Nails®. We already saw a decrease and expect a future decrease in this respective complication.

Many authors cite the postoperative Böhler's angle as a relevant factor for the outcome after calcaneal fracture [5, 6, 10, 28, 34, 35]. Su et al. [35] describe a significant correlation with the functional recovery. This opinion is however controversial. Biz et al. [7] conclude that the postoperative Böhler's angle does not correlate with the clinical outcome. In our study, patients with a postoperative Böhler's angle < 20°—independent of the group—had a worse outcome measured by the AOFAS ankle-hindfoot scale.

According to Rammelt et al. [12], the most important indicator of prognosis is the postoperative status of the subtalar joint. Other authors consider the meticulous restoration of the subtalar joint congruity to be crucial for the functional outcome [5, 6, 24]. Our results were comparably good in both groups regarding the functional outcome as measured with the AOFAS ankle-hindfoot scale.

Many authors use the AOFAS ankle-hindfoot scale to assess the outcome after calcaneal fractures [5, 7, 9, 10, 19, 22, 28]. Studies report average results in the AOFAS ankle-hindfoot scale between 65 and 85 points [28]. Zwipp et al. [24] report average results of 89.5 points at 6-month and 92.6 points at 12-month follow-up using the C-Nail®. Secondary subtalar arthroses or arthrodeses were not observed. Zeman et al. [1] achieved predominantly excellent and good results with both plate and C-Nail. Our patients achieved an average of 79.4 points at 6-month follow-up and thus good results, but our functional results are somewhat worse than the results of Zwipp et al. [24] and Zeman et al. [1]. However, we have treated significantly more Sanders IV fractures. In the current literature, there is unanimous opinion that Sanders IV fractures have a poorer functional outcome [5, 7, 27]. In relation to the severity of injury in our patients, we consider the functional outcomes to be good.

In summary, there are many factors that can influence the complication rate and the outcome, e.g., the duration of surgery, the surgical experience, the postoperative Böhler's angle, and the restoration of the subtalar joint.

The minimally invasive implantation of the nail and the reduction of the subtalar articular surface via a sinus tarsi approach appear advantageous.

There are limitations to our study. First of all, it is a retrospective observational study, however with a control group. The two main groups are only comparable to a limited extent, since significant differences in age, fracture classification, and preoperative Böhler's angle

were found. Nevertheless, the results were verified in our subgroup analysis with matched pairs. There is also no standardized follow-up protocol. As a consequence, the level of evidence is weak. The informative value of the AOFAS score is limited due to a follow-up < 12 months in most patients. In general, a longer follow-up would have been desirable to fully assess secondary complications such as subtalar arthroses and arthrodesis as well as functional outcome. The patients will be monitored further. Finally, extrapolation of our results can be difficult, because our patient collective is not representative. Sanders IV is the most common fracture type in our institution. Furthermore, if an orthopedic surgeon has a small number of cases, the learning curve may be flatter. General challenges however, e.g., risk of wound edge necrosis or wound infection, are transferable.

However, in our opinion, this study enlarges the existing knowledge including skills and pitfalls of this implant. The C-nail is a relatively new implant. Most of the existing studies reported of a small patient number. There has been only one comparative study up to now (comparing C-nail with well-established plate osteosynthesis). Our approach showed comparable results to those of previously performed studies. In addition, we demonstrated that the C-nail is an adequate osteosynthesis even in complex fractures, not only in Sanders type II fractures.

Conclusion

The early-postoperative complication rate was significantly lower in the C-Nail group. Because of the possibility of minimally invasive implantation and the high primary stability, we consider the C-Nail® to be a good and safe implant for the treatment of calcaneal fractures, even in Sanders IV fractures. Long-term analysis of this new implant including elaboration on functional outcome is planned.

Acknowledgements

We acknowledge support by the Open Access Publication Fund of the University of Duisburg-Essen.

Authors' contributions

ES: Conceived and designed the study. Acquisition of data. Drafted the manuscript. WM: Conceived and designed the study. Acquisition of data. Drafted the manuscript. RL: Analysis and interpretation of data. Revised the manuscript. SL: Contributed to study design. Revised the manuscript. MG: Contributed to study design. Revised the manuscript. BM: Contributed to study design. Revised the manuscript. NB: Contributed to study design. Revised the manuscript. MD: Contributed to study design. Revised the manuscript. All authors read and approved the final manuscript.

Funding

This research did not receive any specific grant from funding agencies in the public, commercial, or not-for-profit sectors.

Availability of data and materials

The datasets analyzed during the current study are available from the corresponding author on reasonable request.

Declarations

Ethics approval and consent to participate

This study was favorably evaluated by the Ethics Committee of Witten/Herdecke University (No. 210/2019).

Consent for publication

We obtained informed consent from the analyzed patients.

Competing interests

The authors declare no competing interests.

Author details

¹Department of Orthopedic and Trauma Surgery, BG Klinikum Duisburg, University of Duisburg-Essen, Großenbaumer Allee 250, 47249 Duisburg, Germany. ²Department of Trauma, Hand and Reconstructive Surgery, University Hospital Essen, University of Duisburg-Essen, Essen, Germany. ³Institute for Research in Operative Medicine (IFOM), University of Witten/Herdecke, Cologne, Germany.

Received: 15 January 2021 Accepted: 10 March 2021

Published online: 20 March 2021

References

- Zeman J, Zeman P, Matejka T, Belatka J, Matejka J. Comparison of Lcp and intramedullary nail osteosynthesis in calcaneal fractures. *Acta Orthop Bras*. 2019;27(6):288–93.
- Sanders R, Vaupel ZM, Erdogan M, Downes K. Operative treatment of displaced intra-articular calcaneal fractures: long-term (10–20 years) results in 108 fractures using a prognostic CT classification. *J Orthop Trauma*. 2014; 28(10):551–63.
- Rammelt S, Amlang M, Barthel S, Gavlik JM, Zwipp H. Percutaneous treatment of less severe intra-articular calcaneal fractures. *Clin Orthop Relat Res*. 2010;468(4):983–90.
- Mehta CR, An VVG, Phan K, Sivakumar B, Kanawati AJ, Suthersan M. Extensile lateral versus sinus tarsi approach for displaced, intra-articular calcaneal fractures: a meta-analysis. *J Orthop Surg Res*. 2018;13(1):243.
- Zhang W, Lin F, Chen E, Xue D, Pan Z. Operative versus nonoperative treatment of displaced intra-articular calcaneal fractures: a meta-analysis of randomized controlled trials. *J Orthop Trauma*. 2016;30(3):e75–81.
- Buckley R, Tough S, McCormack R, Pate G, Leighton R, Petrie D, Galpin R. Operative compared with nonoperative treatment of displaced intra-articular calcaneal fractures: a prospective, randomized, controlled multicenter trial. *J Bone Joint Surg Am*. 2002;84(10):1733–44.
- Biz C, Barison E, Ruggieri P, Iacobellis C. Radiographic and functional outcomes after displaced intra-articular calcaneal fractures: a comparative cohort study among the traditional open technique (ORIF) and percutaneous surgical procedures (PS). *J Orthop Surg Res*. 2016;11(1):92.
- Rammelt S, Zwipp H. Calcaneus fractures: facts, controversies and recent developments. *Injury*. 2004;35(5):443–61.
- Jin C, Weng D, Yang W, He W, Liang W, Qian Y. Minimally invasive percutaneous osteosynthesis versus ORIF for Sanders type II and III calcaneal fractures: a prospective, randomized intervention trial. *J Orthop Surg Res*. 2017;12(1):10.
- van Hove S, Poeze M. Outcome of minimally invasive open and percutaneous techniques for repair of calcaneal fractures: a systematic review. *J Foot Ankle Surg*. 2016;55(6):1256–63.
- Xia S, Wang X, Lu Y, Wang H, Wu Z, Wang Z. A minimally invasive sinus tarsi approach with percutaneous plate and screw fixation for intra-articular calcaneal fractures. *Int J Surg*. 2013;11(10):1087–91.
- Rammelt S, Gavlik JM, Barthel S, Zwipp H. The value of subtalar arthroscopy in the management of intra-articular calcaneus fractures. *Foot Ankle Int*. 2002;23(10):906–16.
- Popelka V, Zamborsky R. Operative treatment algorithm for intra-articular calcaneal fractures. *Acta Orthop Belg*. 2018;84(4):469–78.
- Clare MP, Sanders RW. Calcaneus fractures. *Unfallchirurg*. 2011;114(10): 869–76.
- Reinhardt S, Martin H, Ulmar B, Dobe S, Zwipp H, Rammelt S, Richter M, Pompach M, Mittlmeier T. Interlocking nailing versus interlocking plating in intra-articular calcaneal fractures: a biomechanical study. *Foot Ankle Int*. 2016;37(8):891–7.
- Pompach M, Carda M, Amlang M, Zwipp H. Treatment of calcaneal fractures with a locking nail (C-Nail). *Oper Orthop Traumatol*. 2016;28(3):218–30.
- Yu X, Pang QJ, Chen L, Yang CC, Chen XJ. Postoperative complications after closed calcaneus fracture treated by open reduction and internal fixation: a review. *J Int Med Res*. 2014;42(1):17–25.
- Basile A, Albo F, Via AG. Comparison between sinus tarsi approach and extensile lateral approach for treatment of closed displaced intra-articular calcaneal fractures: a multicenter prospective study. *J Foot Ankle Surg*. 2016; 55(3):513–21.
- Kline AJ, Anderson RB, Davis WH, Jones CP, Cohen BE. Minimally invasive technique versus an extensile lateral approach for intra-articular calcaneal fractures. *Foot Ankle Int*. 2013;34(6):773–80.
- Backes M, Schepers T, Beerekamp MS, Luitse JS, Goslings JC, Schep NW. Wound infections following open reduction and internal fixation of calcaneal fractures with an extended lateral approach. *Int Orthop*. 2014; 38(4):767–73.
- Schepers T. The sinus tarsi approach in displaced intra-articular calcaneal fractures: a systematic review. *Int Orthop*. 2011;35(5):697–703.
- Yeo JH, Cho HJ, Lee KB. Comparison of two surgical approaches for displaced intra-articular calcaneal fractures: sinus tarsi versus extensile lateral approach. *BMC Musculoskelet Disord*. 2015;16:63.
- Nosewicz T, Knupp M, Barg A, Maas M, Bolliger L, Goslings JC, Hintermann B. Mini-open sinus tarsi approach with percutaneous screw fixation of displaced calcaneal fractures: a prospective computed tomography-based study. *Foot Ankle Int*. 2012;33(11):925–33.
- Zwipp H, Pasa L, Zilka L, Amlang M, Rammelt S, Pompach M. Introduction of a new locking nail for treatment of intra-articular calcaneal fractures. *J Orthop Trauma*. 2016;30(3):e88–92.
- Amlang MH, Rammelt S. Calcaneal nail C-nail. *Unfallchirurg*. 2016;119(3): 239–44.
- Amlang M, Zwipp H, Pompach M, Rammelt S. Interlocking nail fixation for the treatment of displaced intra-articular calcaneal fractures. *JBJS Essent Surg Tech*. 2017;7(4):e33.
- Gusic N, Fedel I, Darabos N, Lovric Z, Bukvic N, Bakota B, Lemac D. Operative treatment of intra-articular calcaneal fractures: anatomical and functional outcome of three different operative techniques. *Injury*. 2015; 46(Suppl 6):S130–3.
- De Groot R, Frima AJ, Schepers T, Roerdink WH. Complications following the extended lateral approach for calcaneal fractures do not influence mid- to long-term outcome. *Injury*. 2013;44(11):1596–600.
- Chen L, Zhang G, Hong J, Lu X, Yuan W. Comparison of percutaneous screw fixation and calcium sulfate cement grafting versus open treatment of displaced intra-articular calcaneal fractures. *Foot Ankle Int*. 2011;32(10): 979–85.
- Takasaka M, Bittar CK, Mennucci FS, de Mattos CA, Zabeu JL. Comparative study on three surgical techniques for intra-articular calcaneal fractures: open reduction with internal fixation using a plate, external fixation and minimally invasive surgery. *Rev Bras Ortop*. 2016;51(3):254–60.
- DeWall M, Henderson CE, McKinley TO, Phelps T, Dolan L, Marsh JL. Percutaneous reduction and fixation of displaced intra-articular calcaneus fractures. *J Orthop Trauma*. 2010;24(8):466–72.
- Al-Mudhaffar M, Prasad CV, Mofidi A. Wound complications following operative fixation of calcaneal fractures. *Injury*. 2000;31(6):461–4.
- Court-Brown CM, Schmied M, Schutte BG. Factors affecting infection after calcaneal fracture fixation. *Injury*. 2009;40(12):1313–5.
- Swords M, Shank J, Fraticelli N, Benirschke S. Late treatment of displaced intra-articular calcaneus fractures: successful management with anatomic reduction. *J Orthop Trauma*. 2020;34(Suppl 1):S21–5.
- Su Y, Chen W, Zhang T, Wu X, Wu Z, Zhang Y. Bohler's angle's role in assessing the injury severity and functional outcome of internal fixation for displaced intra-articular calcaneal fractures: a retrospective study. *BMC Surg*. 2013;13:40.

Publisher's Note

Springer Nature remains neutral with regard to jurisdictional claims in published maps and institutional affiliations.

Terms and Conditions

Springer Nature journal content, brought to you courtesy of Springer Nature Customer Service Center GmbH (“Springer Nature”).

Springer Nature supports a reasonable amount of sharing of research papers by authors, subscribers and authorised users (“Users”), for small-scale personal, non-commercial use provided that all copyright, trade and service marks and other proprietary notices are maintained. By accessing, sharing, receiving or otherwise using the Springer Nature journal content you agree to these terms of use (“Terms”). For these purposes, Springer Nature considers academic use (by researchers and students) to be non-commercial.

These Terms are supplementary and will apply in addition to any applicable website terms and conditions, a relevant site licence or a personal subscription. These Terms will prevail over any conflict or ambiguity with regards to the relevant terms, a site licence or a personal subscription (to the extent of the conflict or ambiguity only). For Creative Commons-licensed articles, the terms of the Creative Commons license used will apply.

We collect and use personal data to provide access to the Springer Nature journal content. We may also use these personal data internally within ResearchGate and Springer Nature and as agreed share it, in an anonymised way, for purposes of tracking, analysis and reporting. We will not otherwise disclose your personal data outside the ResearchGate or the Springer Nature group of companies unless we have your permission as detailed in the Privacy Policy.

While Users may use the Springer Nature journal content for small scale, personal non-commercial use, it is important to note that Users may not:

1. use such content for the purpose of providing other users with access on a regular or large scale basis or as a means to circumvent access control;
2. use such content where to do so would be considered a criminal or statutory offence in any jurisdiction, or gives rise to civil liability, or is otherwise unlawful;
3. falsely or misleadingly imply or suggest endorsement, approval, sponsorship, or association unless explicitly agreed to by Springer Nature in writing;
4. use bots or other automated methods to access the content or redirect messages
5. override any security feature or exclusionary protocol; or
6. share the content in order to create substitute for Springer Nature products or services or a systematic database of Springer Nature journal content.

In line with the restriction against commercial use, Springer Nature does not permit the creation of a product or service that creates revenue, royalties, rent or income from our content or its inclusion as part of a paid for service or for other commercial gain. Springer Nature journal content cannot be used for inter-library loans and librarians may not upload Springer Nature journal content on a large scale into their, or any other, institutional repository.

These terms of use are reviewed regularly and may be amended at any time. Springer Nature is not obligated to publish any information or content on this website and may remove it or features or functionality at our sole discretion, at any time with or without notice. Springer Nature may revoke this licence to you at any time and remove access to any copies of the Springer Nature journal content which have been saved.

To the fullest extent permitted by law, Springer Nature makes no warranties, representations or guarantees to Users, either express or implied with respect to the Springer nature journal content and all parties disclaim and waive any implied warranties or warranties imposed by law, including merchantability or fitness for any particular purpose.

Please note that these rights do not automatically extend to content, data or other material published by Springer Nature that may be licensed from third parties.

If you would like to use or distribute our Springer Nature journal content to a wider audience or on a regular basis or in any other manner not expressly permitted by these Terms, please contact Springer Nature at

onlineservice@springernature.com